

A 28-year-old Male with Complaints of Redness in Right Eye with Proptosis

Bhumireddy Vijaya Madhuri, Akash Rauniyar, Bineeta Parihar, Sonal Saran*

Department of Diagnostic and Interventional Radiology, AIIMS, Rishikesh, Uttarakhand, India

SECTION 1 – QUIZ

Case

A 28-year-old man presented at our hospital reporting redness in his right eye accompanied by proptosis persisting for 6 months [Figure 1]. He also complained of headaches that had gradually developed without a diurnal pattern and were partially relieved by painkillers. There were no reports of fever, neck stiffness, or projectile vomiting. A thorough neurological examination revealed no abnormalities; the patient was fully oriented in time, place, and person and exhibited normal higher mental functions. Ophthalmic assessment revealed proptosis, chemosis, and orbital bruit, with unremarkable visual acuity in both eyes.

Upon questioning, the patient disclosed a history of a road traffic accident 9 months prior, resulting in traumatic injuries, including a fractured mandible and a forehead laceration. Symptoms in the right eye began 3 months after the incident. The patient had no prior history of diabetes or hypertension, and his thyroid profile was within normal limits.

Orbital Doppler ultrasonography findings are depicted in Video 1.

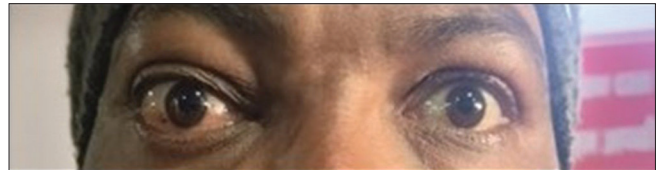


Figure 1: Clinical photograph showing patient's eyes appearing red with proptosis

WHAT IS YOUR IMPRESSION?

Declaration of patient consent

The authors certify that they have obtained all appropriate patient consent form. In the form, the patient has given his consent for his images and other clinical information to be reported in the journal. The patient understands that his name and initials will not be published and due efforts will be made to conceal the identity, but anonymity cannot be guaranteed.

Financial support and sponsorship

Nil.

Conflicts of interest

There are no conflicts of interest.

Address for correspondence: Dr. Sonal Saran,
Department of Diagnostic and Interventional Radiology, AIIMS,
Rishikesh - 249 203, Uttarakhand, India.
E-mail: sonalsaranmalik@gmail.com

Received: 29-04-2024 Revised: 15-05-2024 Accepted: 13-06-2024 Available Online: 13-03-2025

Videos available on <https://journals.lww.com/jmut>

Access this article online

Quick Response Code:



Website:
<https://journals.lww.com/jmut>

DOI:
10.4103/jmu.jmu_50_24

This is an open access journal, and articles are distributed under the terms of the Creative Commons Attribution-NonCommercial-ShareAlike 4.0 License, which allows others to remix, tweak, and build upon the work non-commercially, as long as appropriate credit is given and the new creations are licensed under the identical terms.

For reprints contact: WKHLRPMedknow_reprints@wolterskluwer.com

How to cite this article: Madhuri BV, Rauniyar A, Parihar B, Saran S. A 28-year-old male with complaints of redness in right eye with proptosis. J Med Ultrasound 2025;33:92.